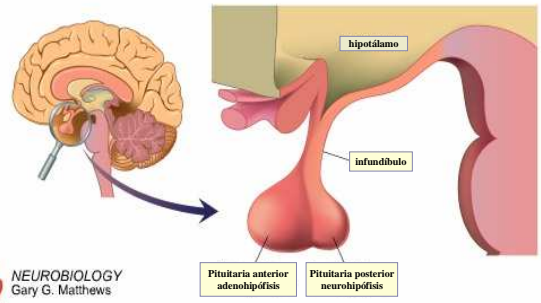
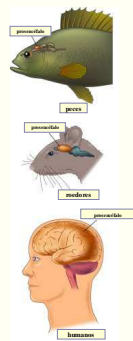
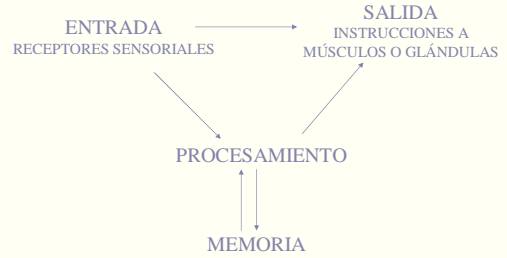
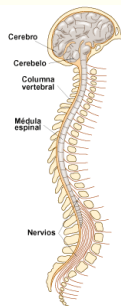


SISTEMA NERVIOSO

Álvaro López

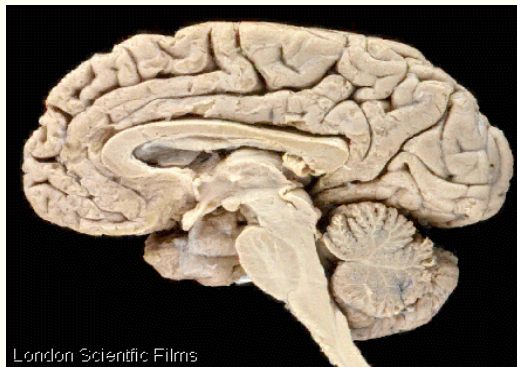


Sistema nervioso central

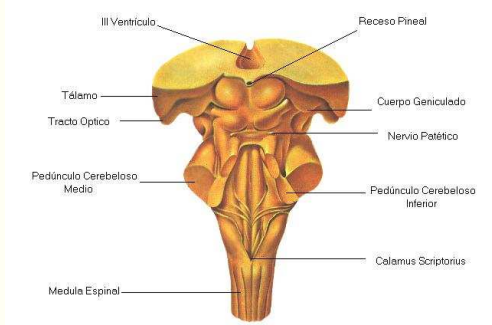
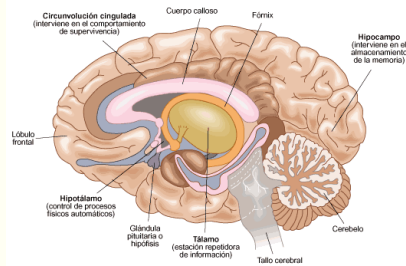


SISTEMA NERVIOSO CENTRAL

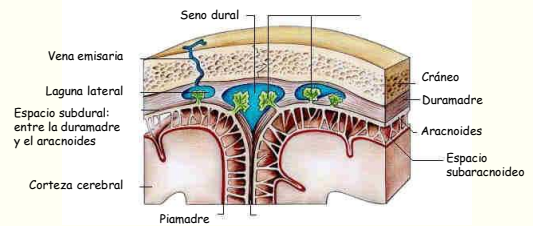
ENCÉFALO: CEREBRO, CEREBELO, BULBO, DIENCÉFALO, ETC.



Corte transversal del encéfalo

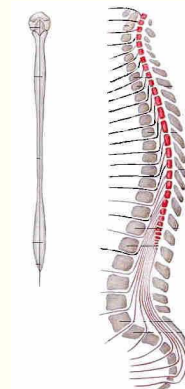


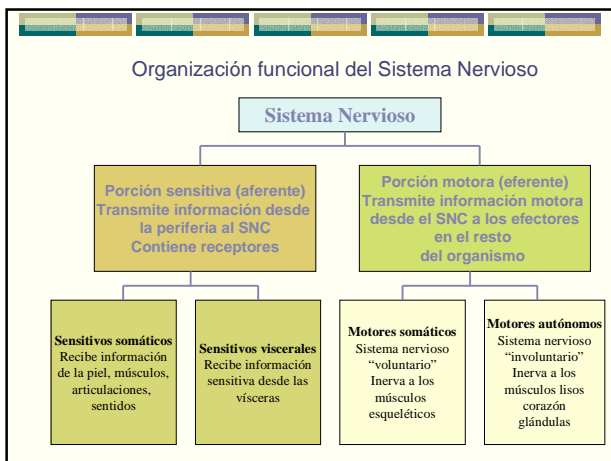
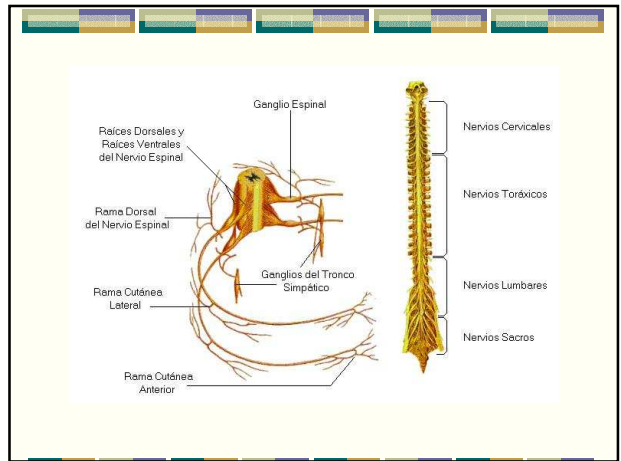
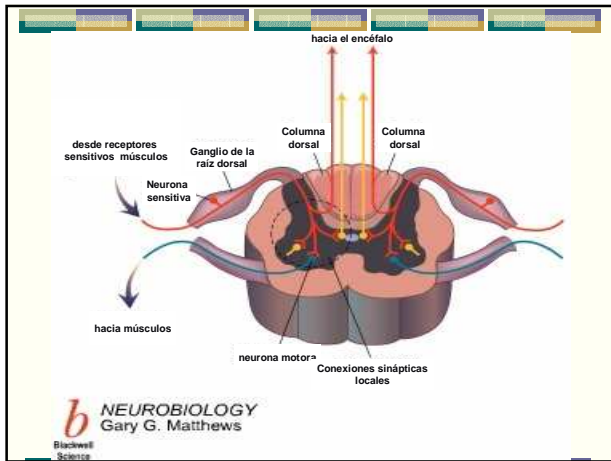
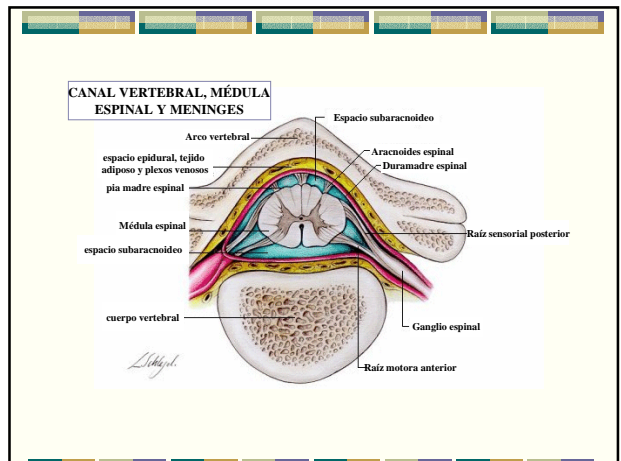
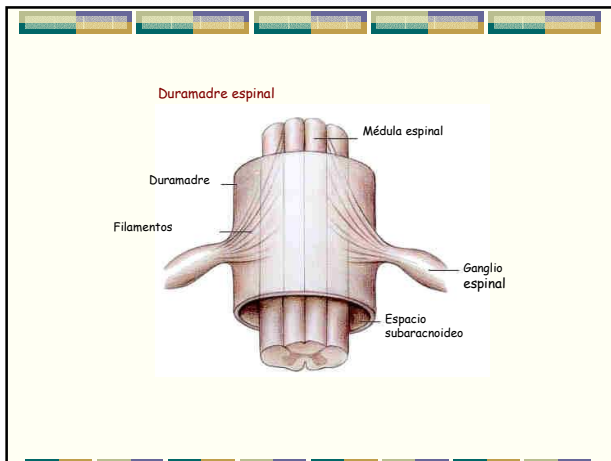
MENINGES



SISTEMA NERVIOSO CENTRAL

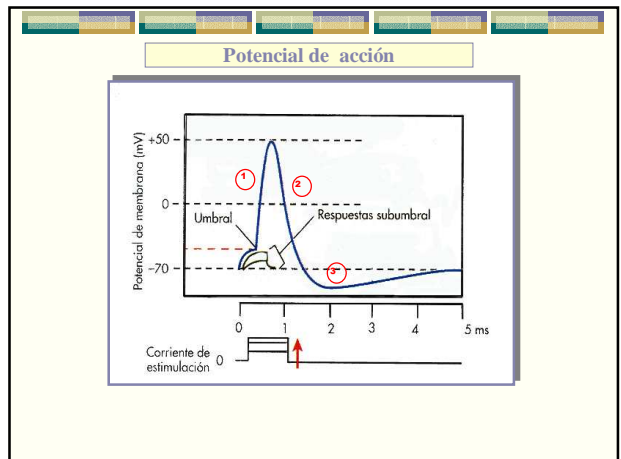
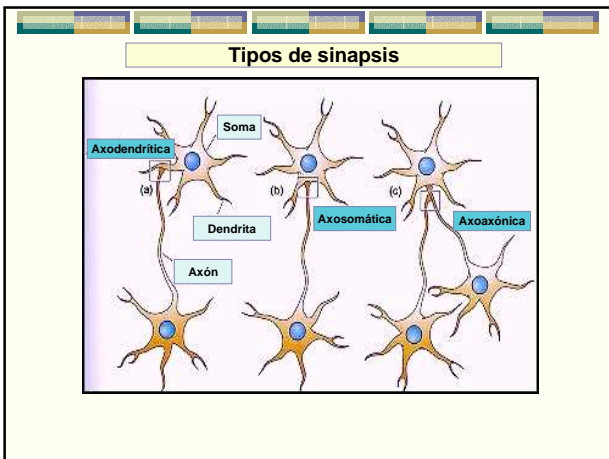
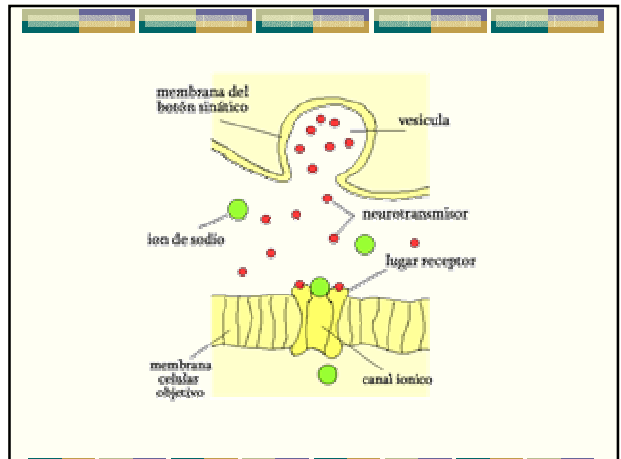
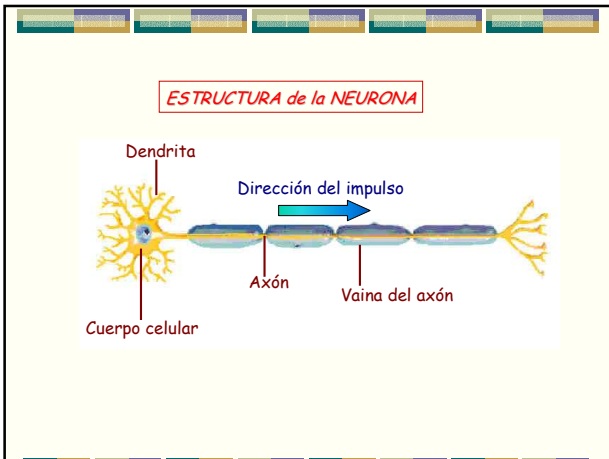
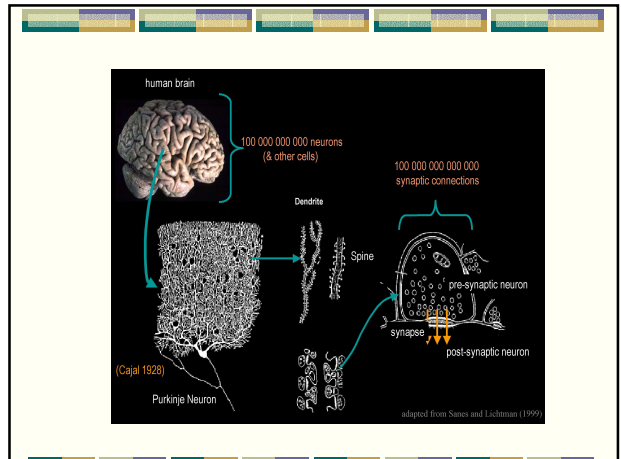
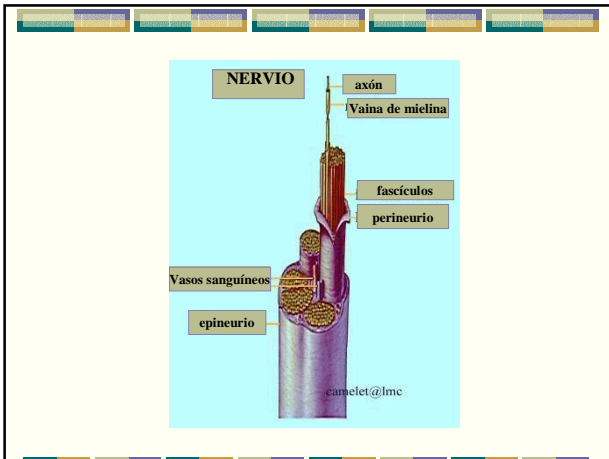
- ENCÉFALO: CEREBRO, CEREBELO, BULBO, DIENCÉFALO, ETC.
- MÉDULA ESPINAL

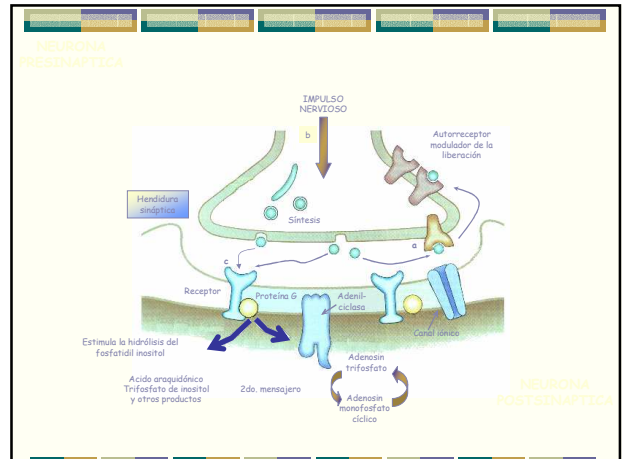
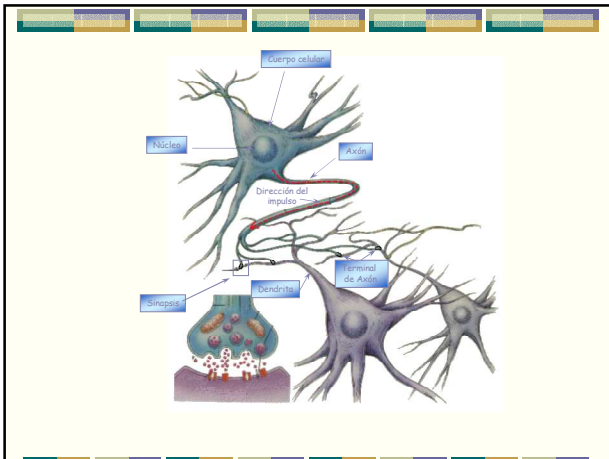




SISTEMA NERVIOSO PERIFÉRICO

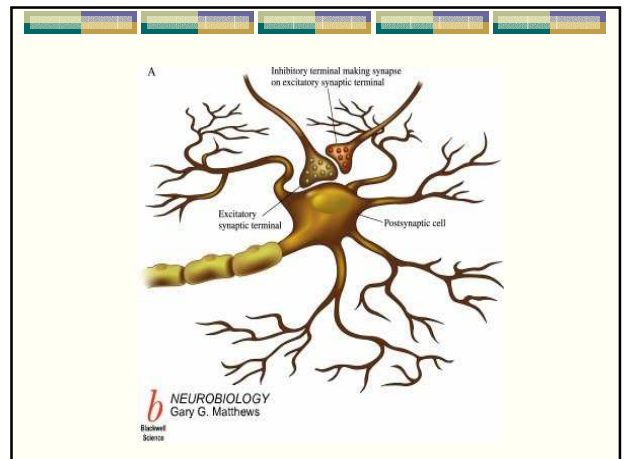
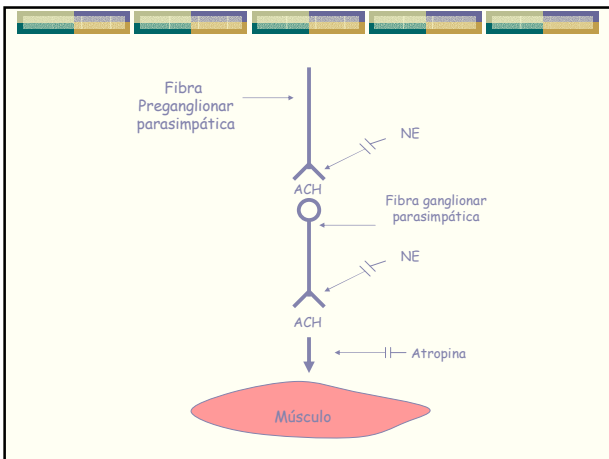
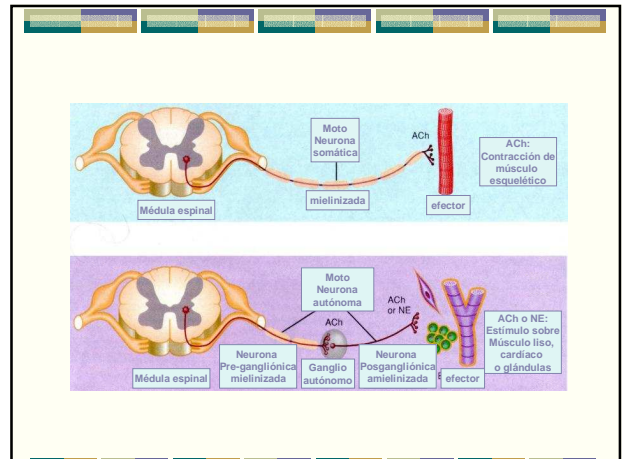
- NERVIOS
- GANGLIOS





SISTEMA NERVIOSO AUTÓNOMO

- SIMPÁTICO: tóraco-lumbar
- PARASIMPÁTICO: cráneo-sacro
- ENTÉRICO



INERVACION AUTONOMA PERIFERICA DE ALGUNAS VISCERAS

